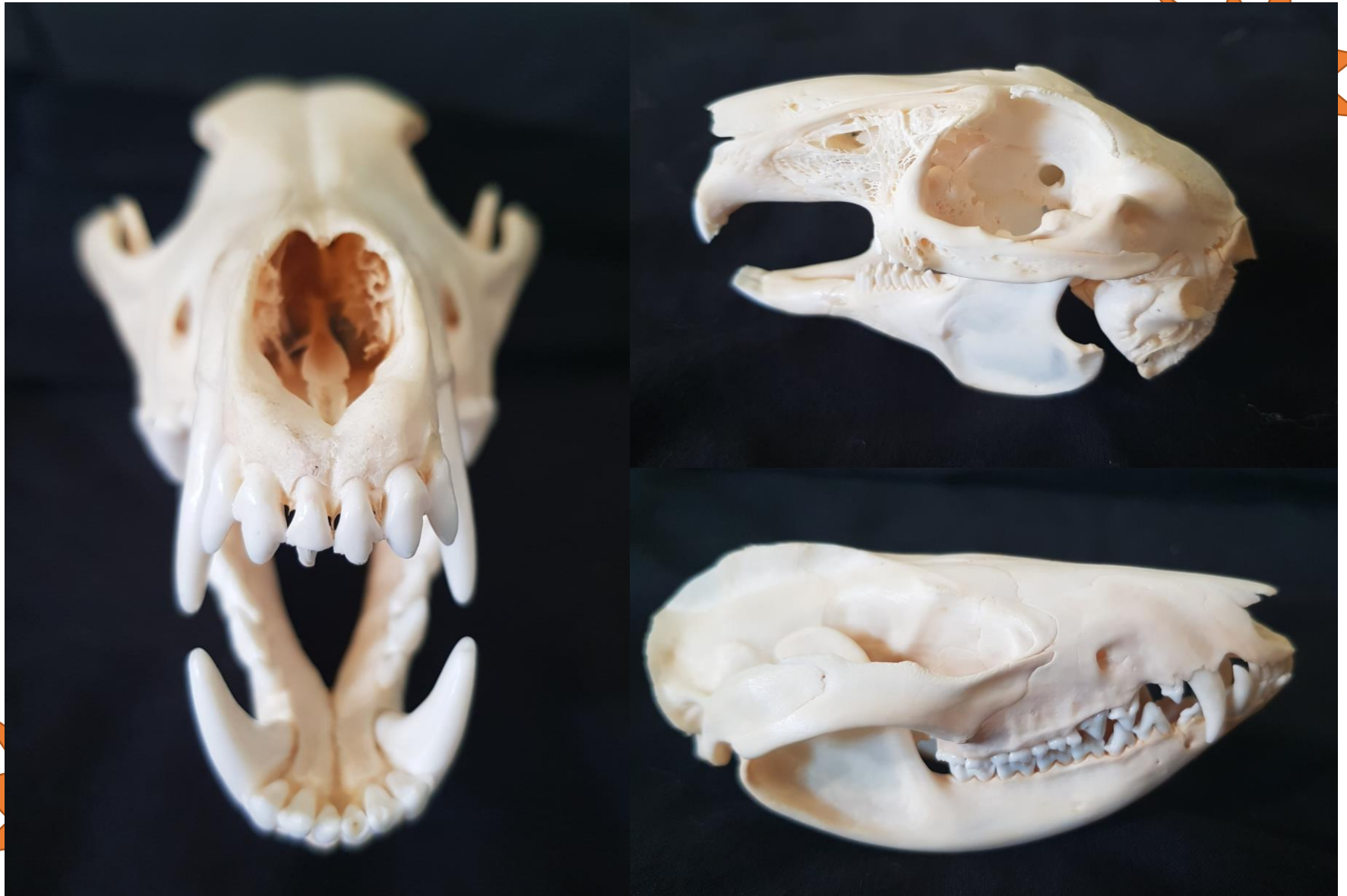

# Key to Common Maryland Mammal Skulls

---



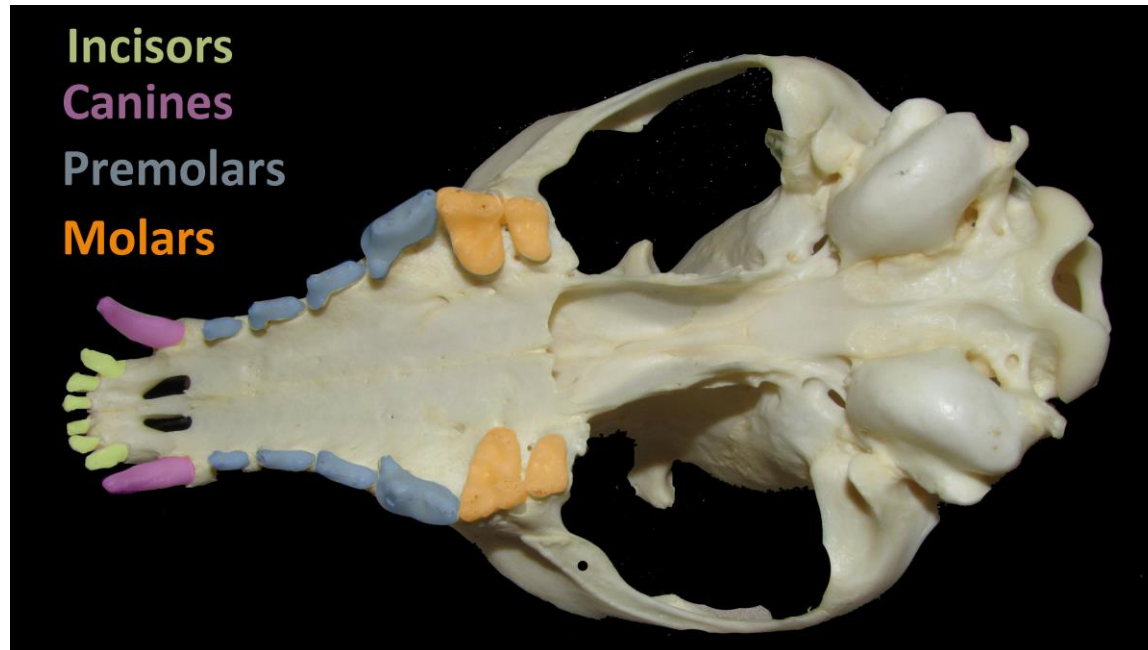
**Kerry Wixted**

2022

# Introduction to Mammal Teeth

Teeth can tell you a lot about an animal, including their main diet. In some animals, like black bears, you can also use teeth to age the animal. There are four main types of teeth, and the number of each type is often written as a fraction known as a dental formula.

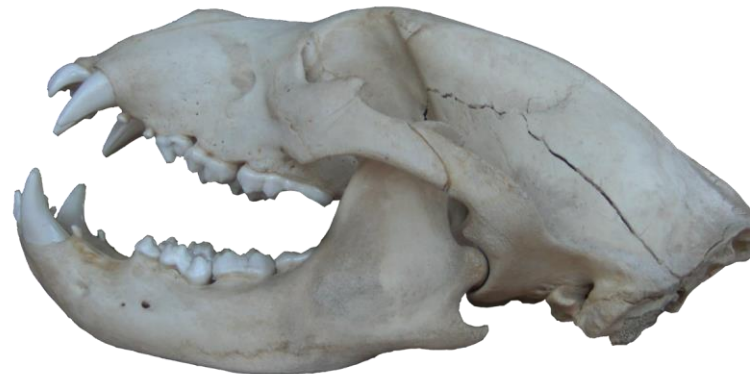- **Incisor**- anterior-most teeth (front teeth) of mammals; used for biting
- **Canine**- elongate, unicuspid tooth; used for grabbing flesh
- **Premolar**- bicuspid teeth situated between canines and molars; used for tearing and grinding
- **Molar**- teeth, typically with 4 cusps, located after premolars; used for grinding
- **Dental formula**- numerical representation of the number of each kind of tooth on one side of the upper and one side of the lower jaw
  - **Example:** The statement 'incisors 5/4' means that there are 5 incisors on top and 4 incisors on the bottom for each side of the jaw
- **Carnassial teeth**- pair of bladelike teeth (last upper molar and first lower molar) that exhibit a shearing action
- **Cheek teeth**- combination of premolars and molars



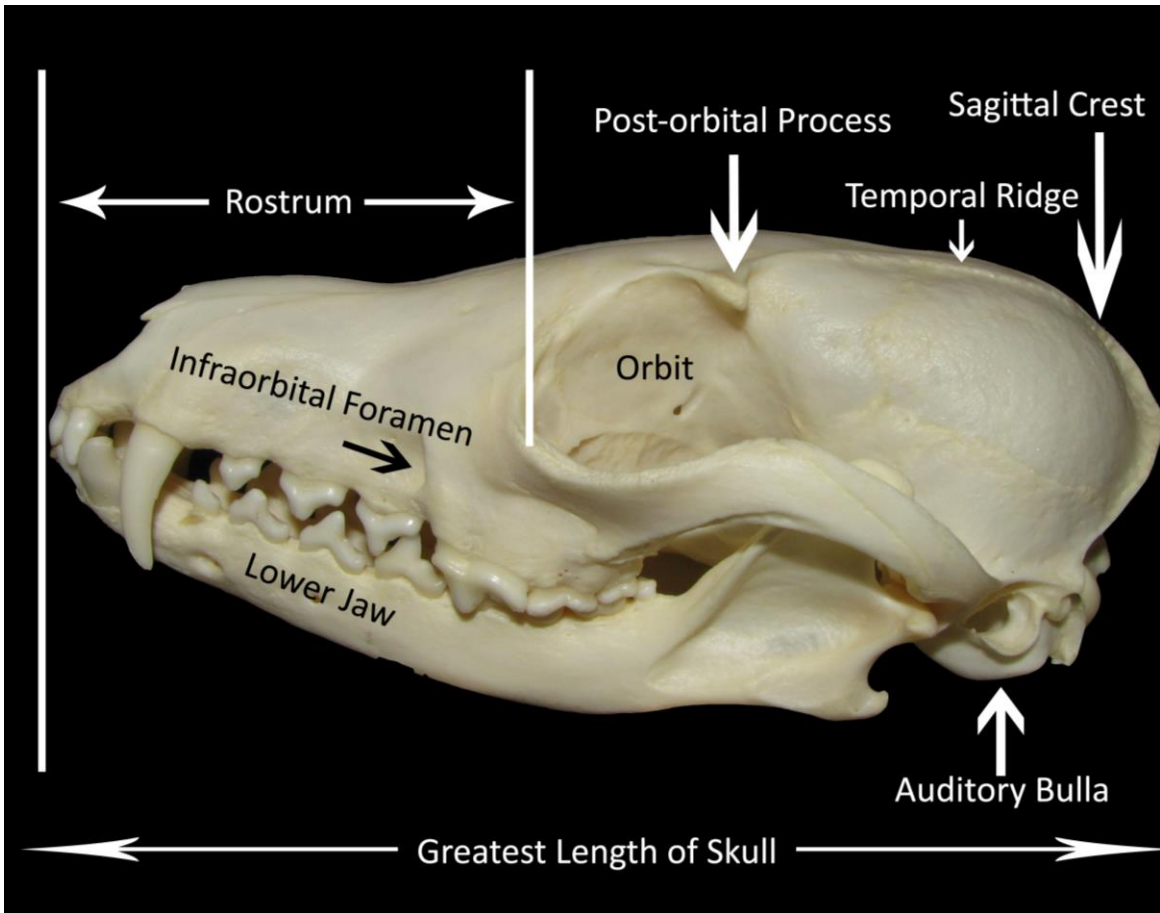
# Introduction to Common Mammal Skull Terms

There are many parts of a skull. Below are definitions for vocabulary words you may encounter with this key:

- **Anterior**- front of skull or lower jaw
- **Auditory bulla (or bullae)**- bony capsule enclosing middle ear
- **Diastema**- a gap or space in the jaw between teeth; used most often to denote gap between incisors and cheek teeth in rodents
- **Foramen**- openings or holes in bone where nerves, blood vessels, and muscles can pass through
- **Foramen magnum**- large opening at the back of a skull which the spinal cord goes through
- **Greatest length of skull**- length from tip of rostrum to the posterior most part of the skull
- **Infraorbital foramen**- opening below the eye; aka infraorbital foramen
- **Mandibular mental foramen**- foramina (openings) located on the anterior surface of the mandible
- **Orbit**- eye socket
- **Paraoccipital process**- a downward-projecting spur from the base of the skull which attaches the muscle used in opening the lower jaw
- **Posterior**- back of skull or lower jaw
- **Post-orbital process**- bony projection by the rear of the orbit
- **Rostral fenestra**- holes on the side of the rostrum; in rabbits, this can look like lacy bone
- **Rostrum**- distance from end of nostrils to orbit (aka nose)
- **Sagittal crest**- raised bony ridge on middle of cranium; well developed in carnivores
- **Temporal ridge**- any of four nearly parallel curved ridges or lines situated two on each side of the skull and chiefly on the parietal bone



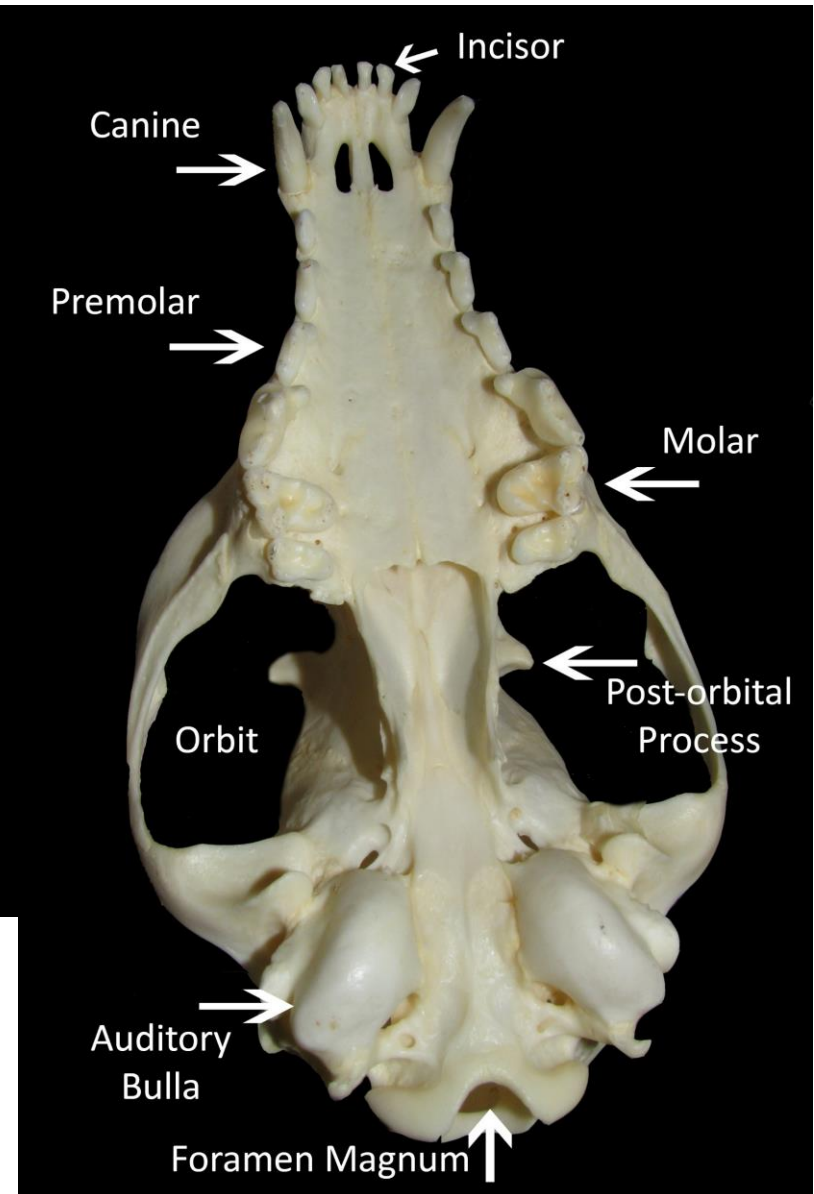
# Introduction to Common Mammal Skull Terms



*Eyes: Forward-facing eyes indicate the mammal is likely a predator while eyes on the side indicate the mammal is likely prey.*

*Rostrum: A long rostrum and/or well developed nasal cavity indicate a good sense of smell.*

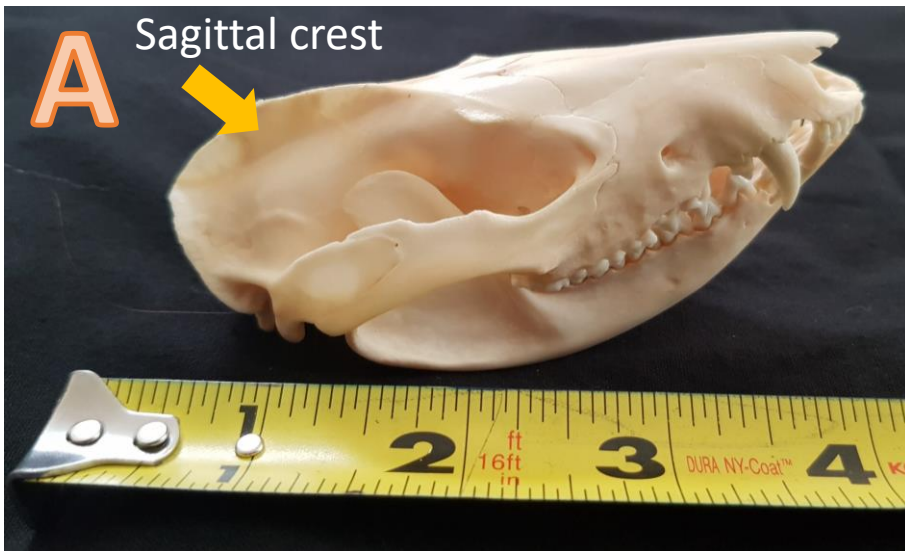
*Auditory bullae (singular= bulla): These help house the inner ear bones which assist with hearing and with balance.*



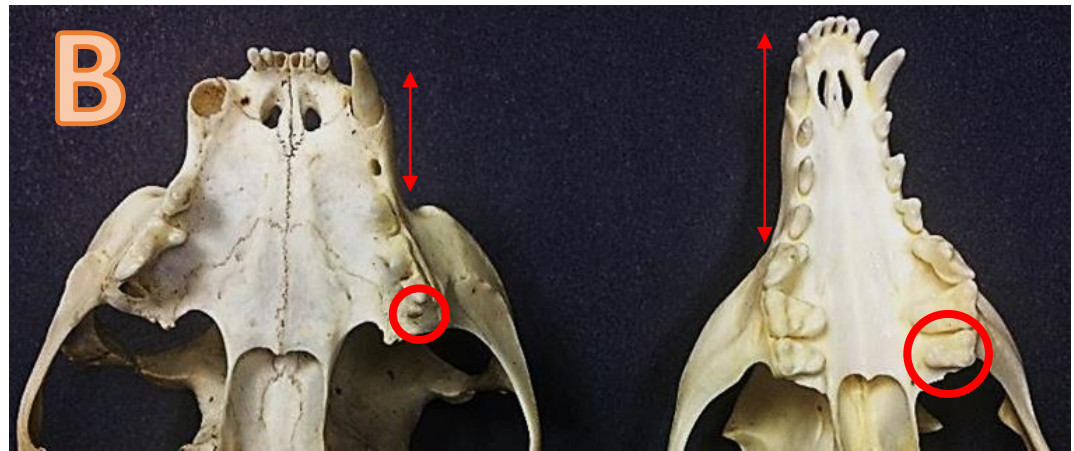


# Key to Common Maryland Mammal Skulls

- 1. Canines present .....2
- 1. Canines absent ..... **Section A**
- 2. Incisors  $5/4$  [dental formula] and large sagittal crest present (Figure A).....**Opossum**
- 2. Incisors not  $5/4$  .....3
- 3. Rostrum (nose) short. Rear, upper molar small and peg-like (Fig. B, left) .....4
- 3. Rostrum short or long. Upper molar(s) not peg-like and robust (Fig. B, right).....5



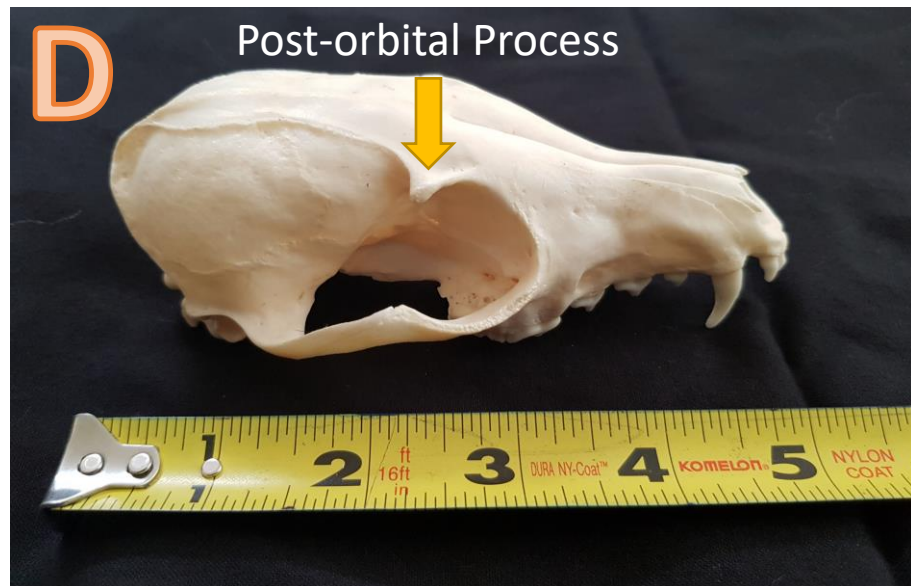
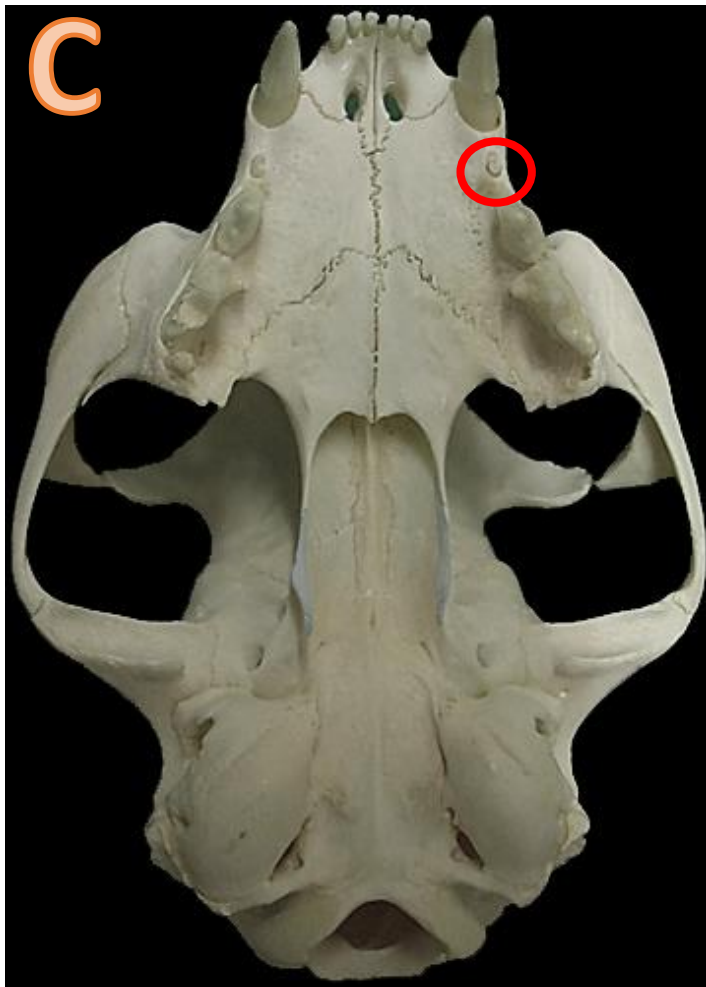
Virginia opossums have 50 teeth, a large sagittal crest and a small braincase.



Felines (left) have short noses and a tiny peg-like molar behind their premolars. Canines (right), have longer noses and larger and more robust rear molars.

## Key to Common Maryland Mammal Skulls

- 4. Has tiny premolar (Fig. C) behind canine; greatest length of skull 77-101 mm (~4").....**House cat**
- 4. Lacks tiny premolar behind canine; greatest length of skull over 101 mm (> 4").....**Bobcat**
- 5. Post-orbital process in front of skull midpoint.....6
- 5. Post-orbital process at or near skull midpoint (Fig. D).....**Section B**

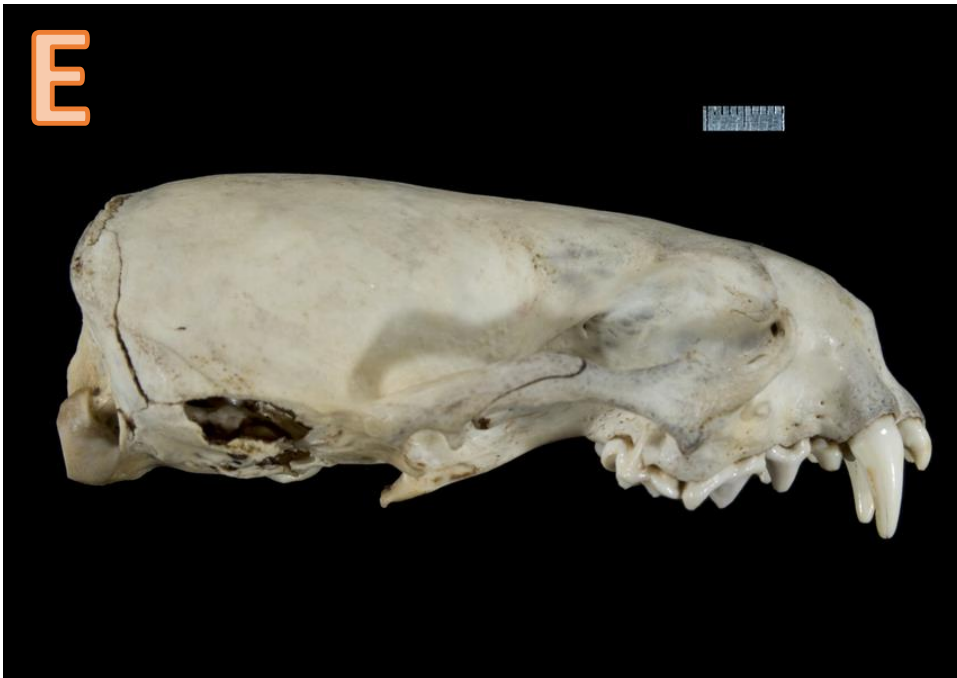

*Housecats (Fig. C) have a small premolar behind their canines. Often, this premolar will fall out in skull specimens but the hole behind the canine will be a sign a tooth was once there.*

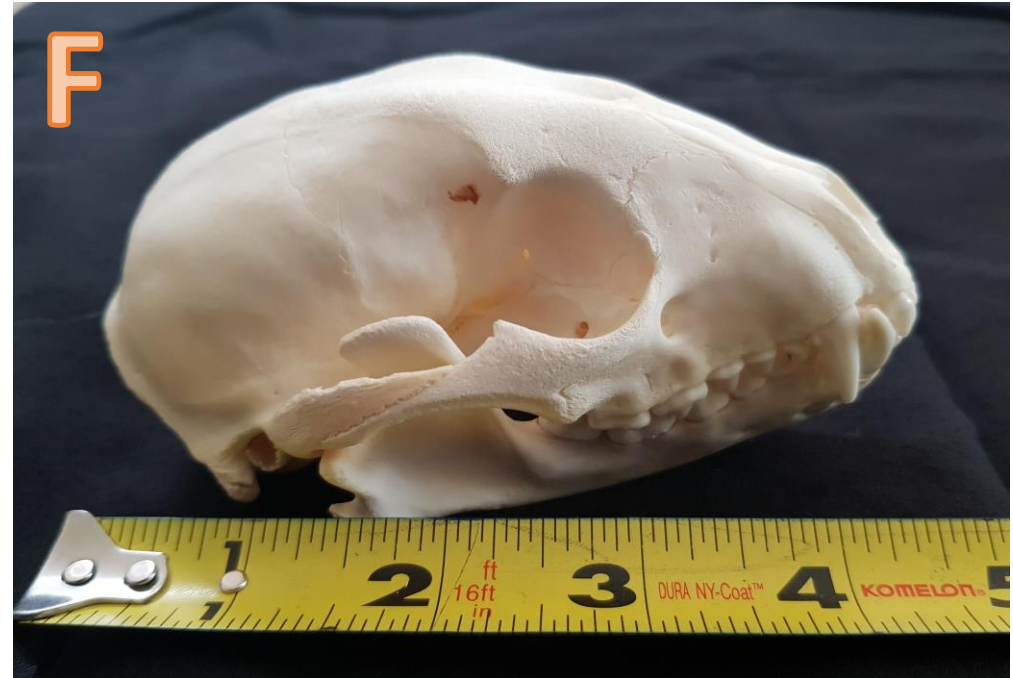*Mustelids (weasels) and raccoons have a short nose and large braincase, but canines have a more evenly distributed skull with the post-orbital process falling close to the middle of the total length of the skull.*

## Key to Common Maryland Mammal Skulls

6. 4-5 upper cheek teeth with less than 40 teeth total (Fig. E) ..... **Section C**
6. 6 or more upper cheek teeth with 40-42 teeth total ..... **7**
7. Greatest length of skull less than 200 mm (~7.8") ..... **Raccoon (Fig. F)**
7. Greatest length of skull more than 200 mm (>7.8") ..... **Black bear**



*Weasels and other mustelids tend to have smaller numbers of molars and premolars than black bears and raccoons. Photo by: Phil Myers CC by NC SA 3.0*



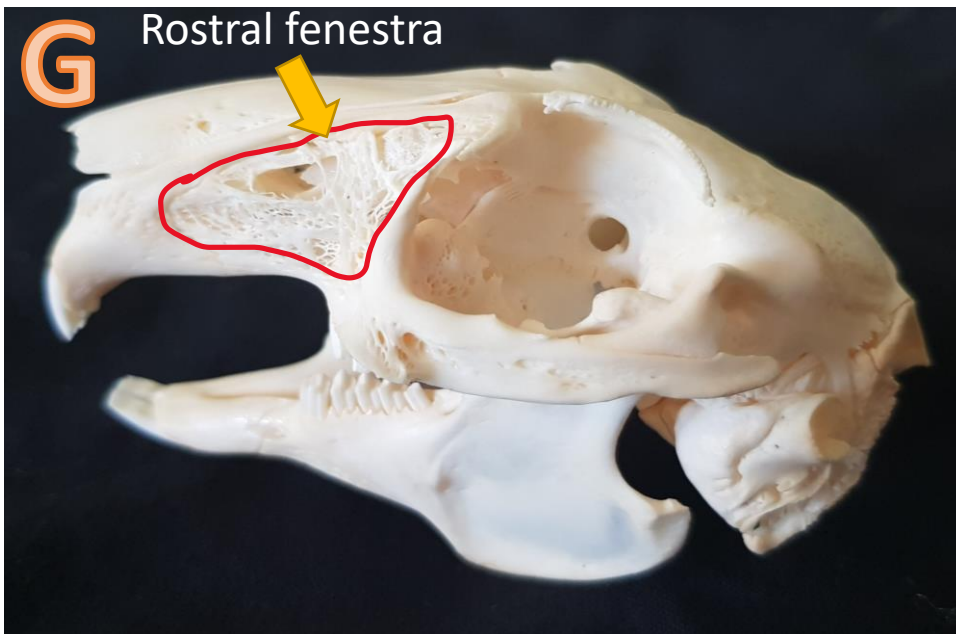
*Raccoon skulls are one of the most common types of skulls you will find in Maryland. They look comparable to black bear skulls, though the two species are not related.*



# Key to Common Maryland Mammal Skulls:

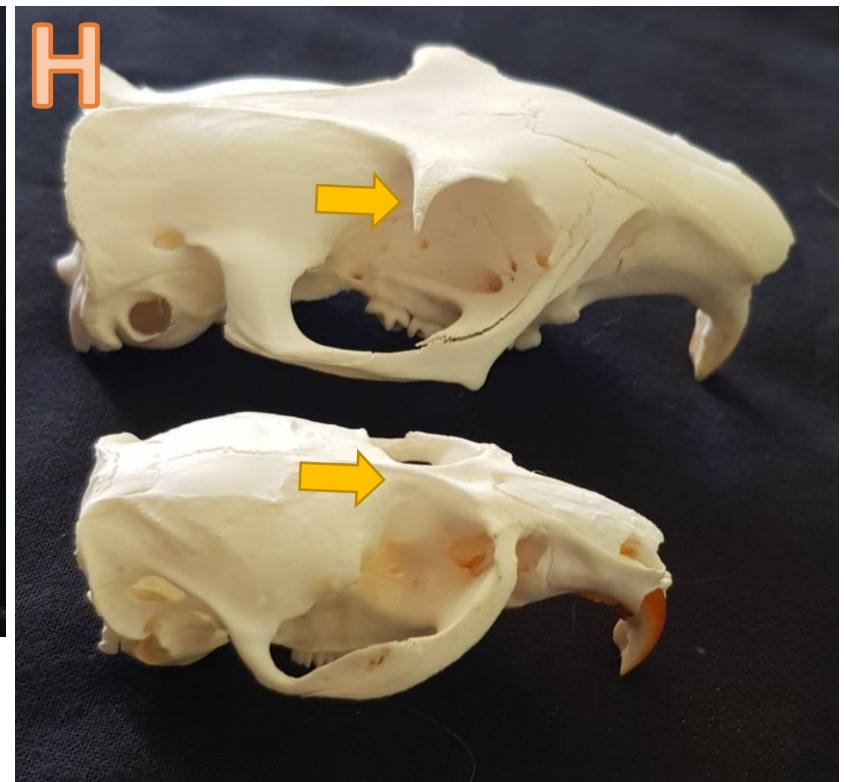
## Section A: Deer, Rabbits, and Rodents

- |  |                           |
|--|---------------------------|
| 1. Upper incisors present.....   | 2                         |
| 1. Upper incisors absent.....  | <b>White-tailed deer</b>  |
| 2. Upper incisors 4 or 6; rostral fenestra present (Fig. G).....             | <b>Eastern cottontail</b> |
| 2. Upper incisors less than 4; rostral fenestra absent.....                  | 3                         |
| 3. Post-orbital process sharply pointed (Fig. H. top) .....                  | 4                         |
| 3. Post-orbital process not sharply pointed or absent (Fig. H. bottom) ..... | 6                         |



*Rabbits (Fig. G) have a peg-like set of upper incisors behind the larger, front set of incisors. Juveniles have 3 sets of upper incisors.*

*Members of the squirrel family (Fig. H, upper photo) have large post-orbital processes.*

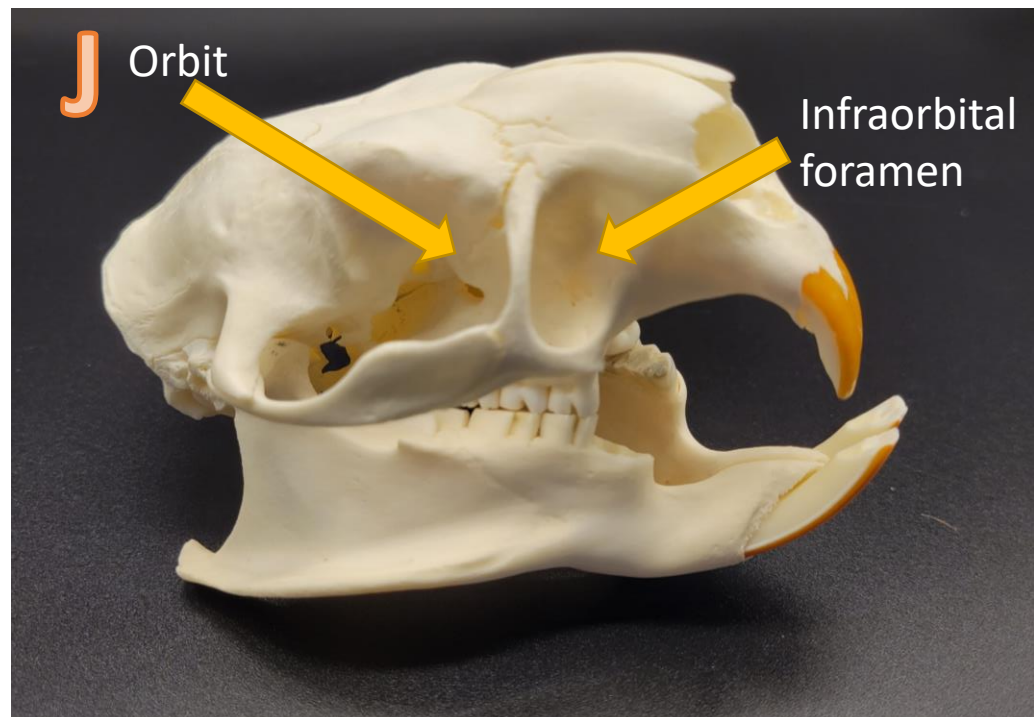
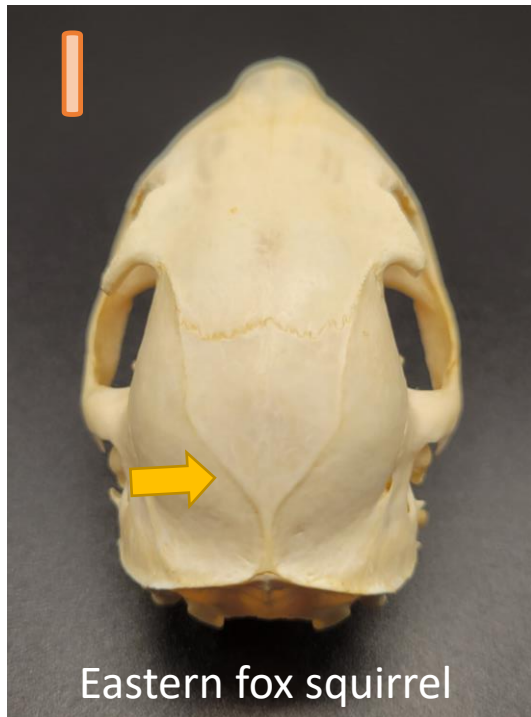



## Key to Common Maryland Mammal Skulls:

### Section A: Deer, Rabbits, and Rodents, Cont'd

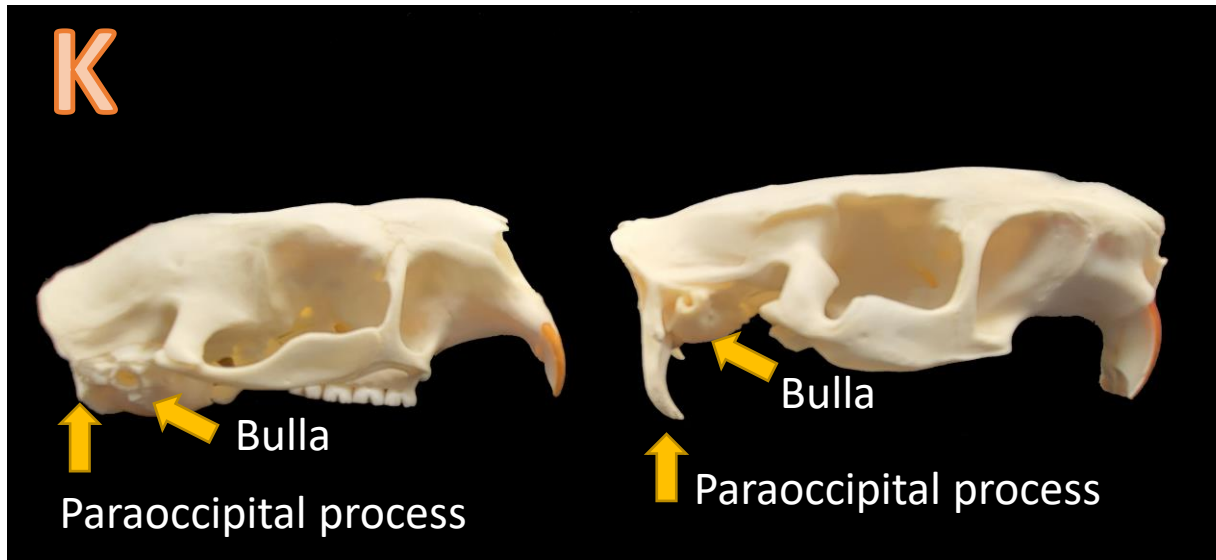
- |   |                              |
|---|------------------------------|
| 4. Greatest length of skull greater than 76 mm (~3").....                 | <b>Groundhog</b>             |
| 4. Greatest length of skull less than 76 mm (<3").....                    | 5                            |
| 5. Developed temporal ridges form a small sagittal crest (Fig. I).....    | <b>Eastern fox squirrel</b>  |
| 5. Temporal ridges not developed; sagittal crest absent.....              | <b>Eastern gray squirrel</b> |
| 6. Infraorbital foramen round and almost as large as orbit (Fig. J) ..... | 7                            |
| 6. Infraorbital foramen often slit-like and smaller than orbit .....      | 8                            |



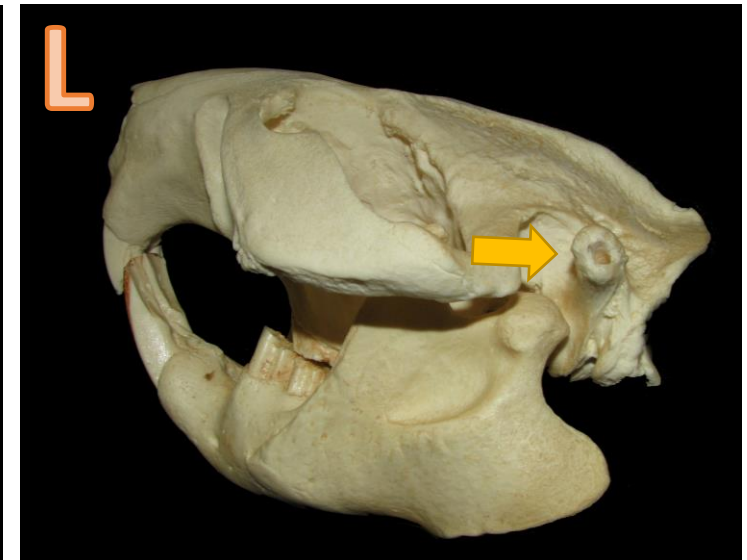
## Key to Common Maryland Mammal Skulls:

### Section A: Deer, Rabbits, and Rodents, Cont'd

- |  |                  |
|--|------------------|
| 7. Paraoccipital process does not extend beyond auditory bullae (Fig. K; left) ..... | <b>Porcupine</b> |
| 7. Paraoccipital process extends beyond auditory bullae (Fig. K; right) .....        | <b>Nutria</b>    |
| 8. Ear canals long and pointed upward (Fig. L).....                                  | <b>Beaver</b>    |
| 8. Ear canals short and not pointed upward.....                                      | <b>Muskrat</b>   |



*All rodents on this page have orange incisors due to iron minerals in their enamel. This makes the teeth strong and allows them to chew on wood and other hard materials.*

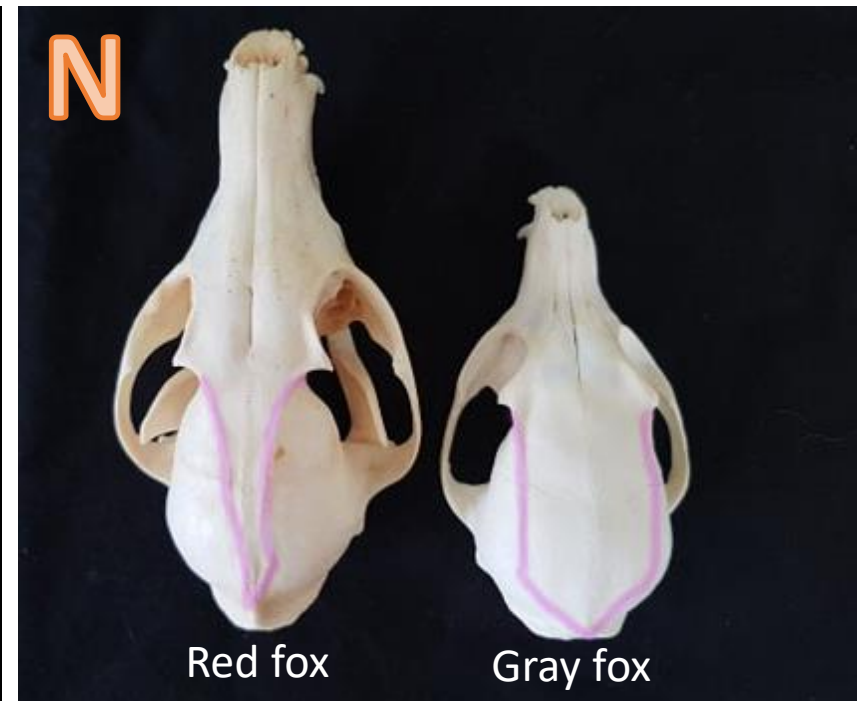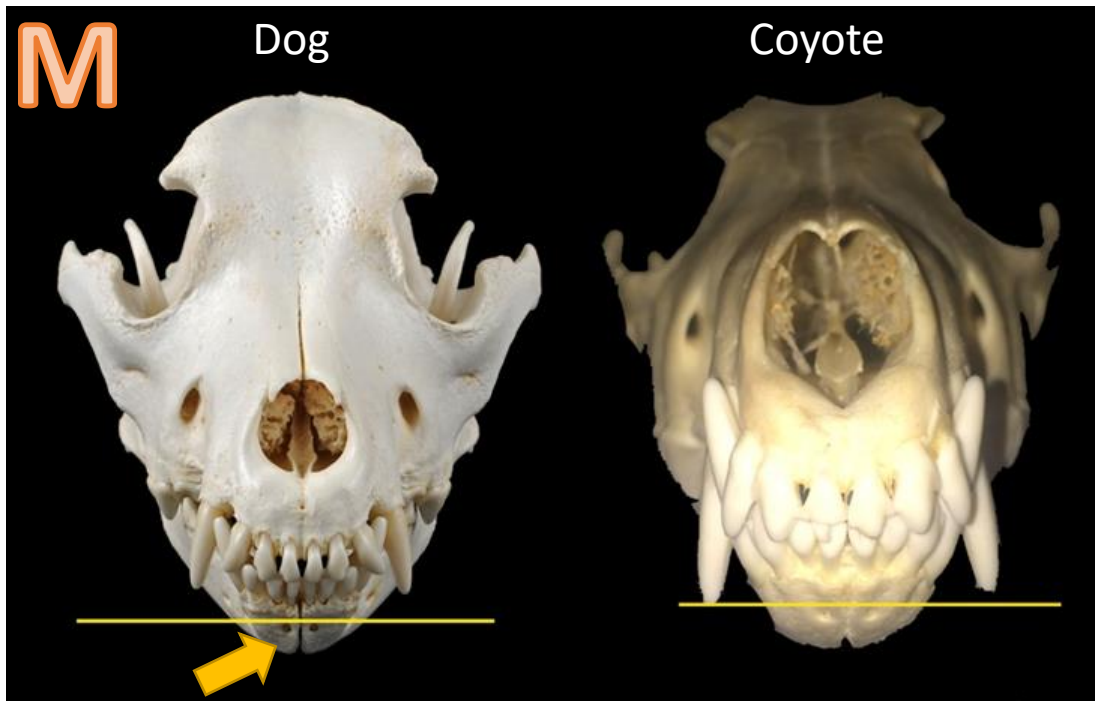


*Beavers are well adapted for an aquatic lifestyle. They have lips behind their incisors which allows them to carry twigs underwater without getting water down their throat! They also have transparent eyelids that act like built-in goggles and can close their ears when they dive underwater.*

## Key to Common Maryland Mammal Skulls:

### Section B: Canids (Dogs, Coyotes & Kin)

- |  |              |
|--|--------------|
| 1. Greatest length of skull greater than 170 mm (>~6.7") .....             | 2            |
| 1. Greatest length of skull less than 170 mm (<~6.7") .....                | 3            |
| 2. Canines do not reach the mandibular mental foramina (Fig. M, left)..... | Domestic dog |
| 2. Canines at past mandibular mental foramina (Fig. M, right).....         | Coyote       |
| 3. Temporal ridges on top of skull form a V-shape (Fig. N, left).....      | Red fox      |
| 3. Temporal ridges on top of skull form a U-shape (Fig. N, right).....     | Gray fox     |

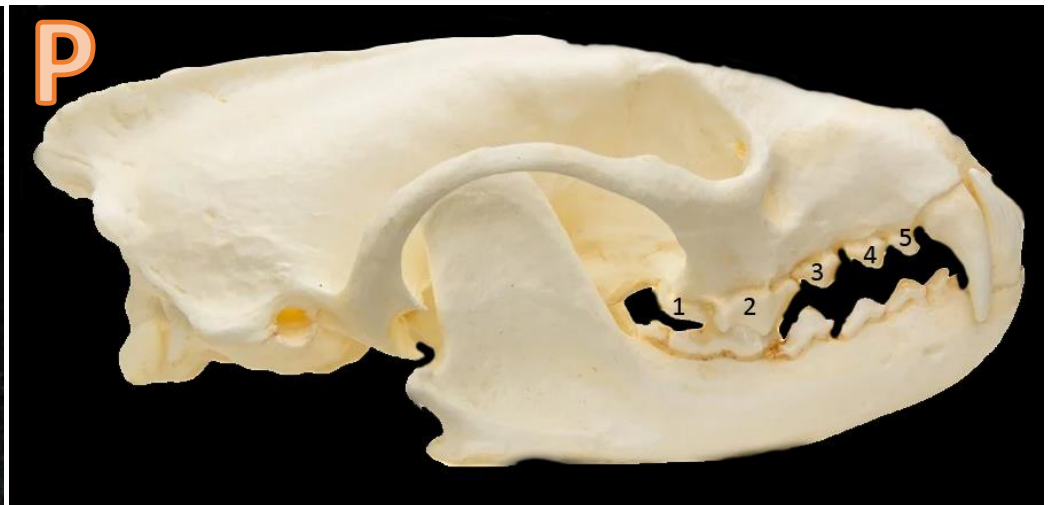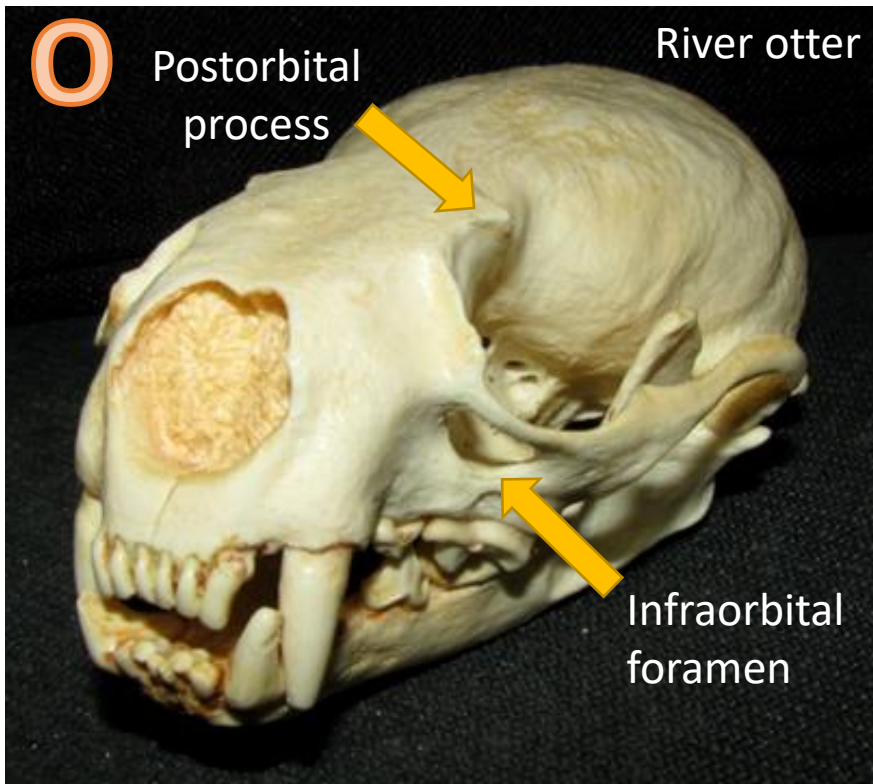


*While the mandibular mental foramina is a good ID trait, many domestic dogs also have sloping foreheads, and some have shortened noses.*

# Key to Common Maryland Mammal Skulls:

## Section C: Mustelids, Cont'd

1. Post-orbital process well developed; infraorbital foramen greater than 8mm in diameter (Fig. O) .....**River otter**
1. Post-orbital process lacking to moderately developed; infraorbital foramen less than 8mm in diameter .....2
2. 5 upper cheek teeth per side; premolars 4/4 (Fig. P) .....**Fisher**
2. 4 upper cheek teeth per side; premolars 2/3 or 3/3.....3



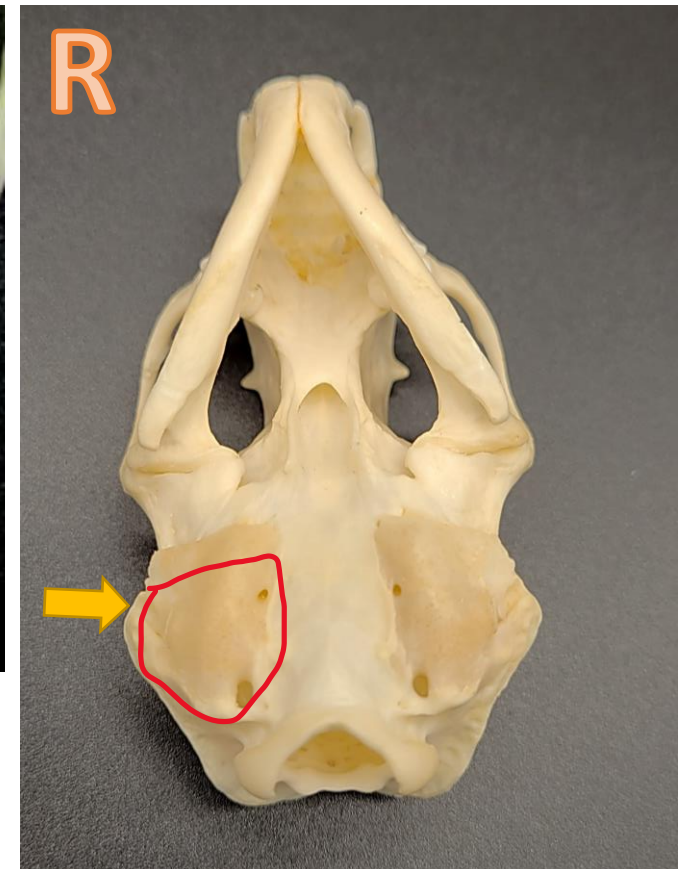
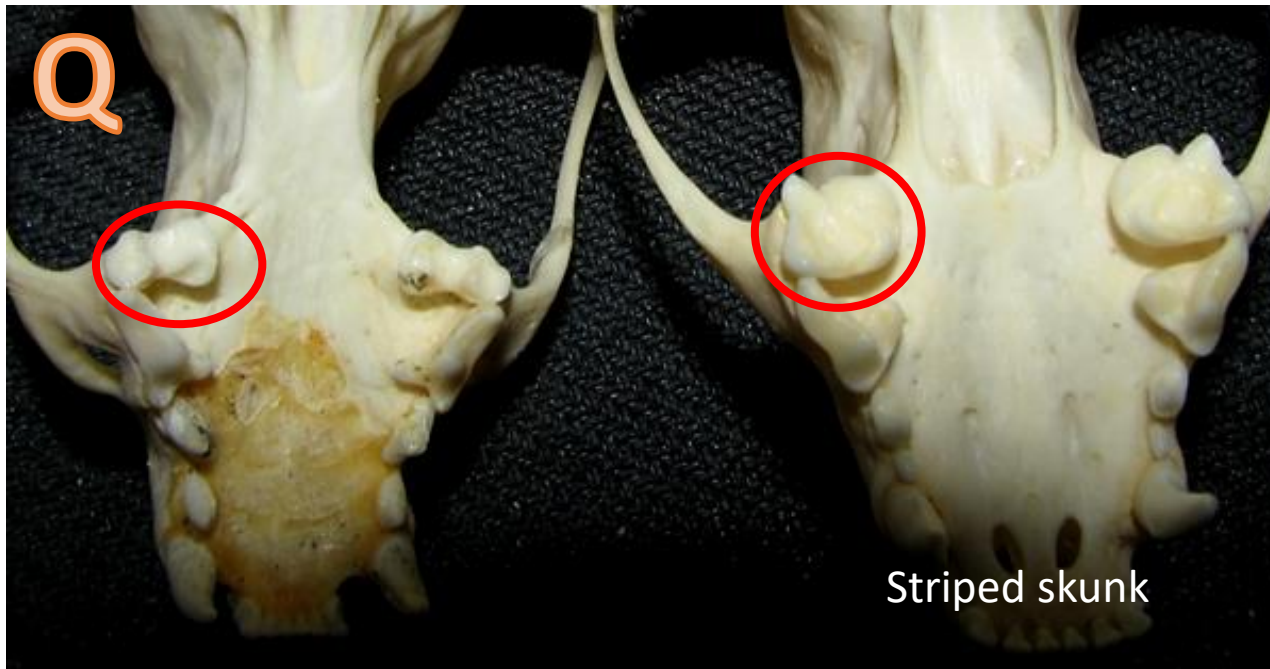
*As fishers mature, the sagittal crest forms. As males age, the crest becomes more prominent and can be used to determine the sex of the animal based on its measurements.*



## Key to Common Maryland Mammal Skulls:

### Section C: Mustelids, Cont'd

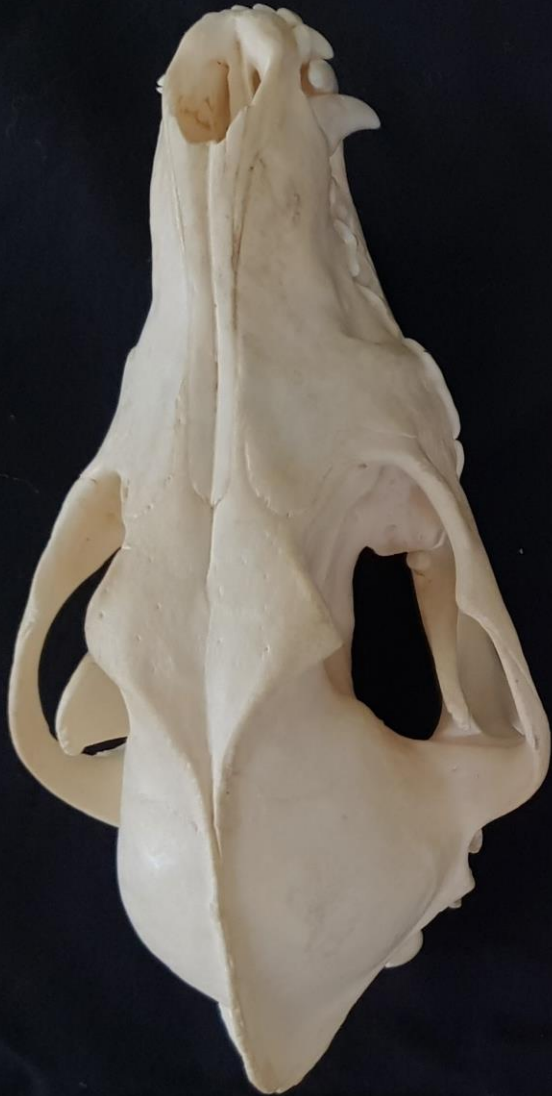- |  |  |
|--|--|
| <p>3. Upper molar dumbbell-shaped (Fig. Q, left); auditory bulla prominent, elongated (Fig. R).....4</p> <p>3. Upper molar rectangular-shaped (Fig. Q, right); auditory bulla flat and not elongated<br/>         ..... <b>Striped skunk</b></p> |  |
| <p>4. Skull over 58mm long (&gt;2.2") ..... <b>Mink</b></p> <p>4. Skull 40-58mm long (~1.5-2.2") ..... <b>Long-tailed weasel</b></p>   |  |



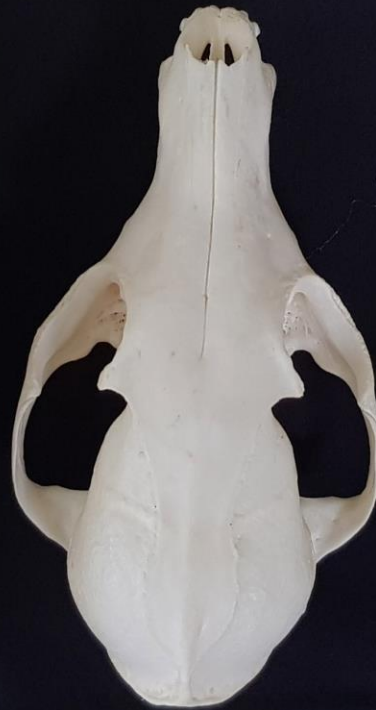*Skunks were once grouped with weasels in the Mustelidae family but now belong to the Mephitidae family. Skunks have teeth more in line with omnivores as evidenced by their flatter, final upper molar. Occasionally, nematodes will infect skunk and mustelid sinuses, causing damage to the sinus bones.*

# Key to Common Maryland Mammal Skulls: Size Comparisons

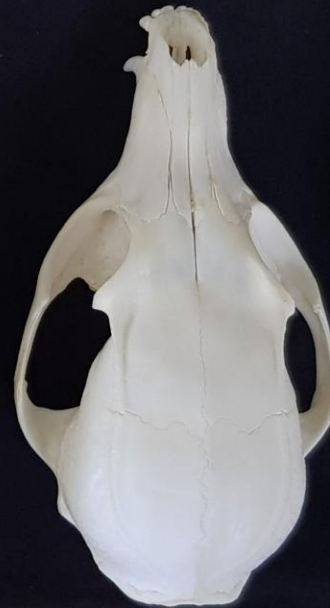Coyote



Red fox



Gray fox



Raccoon

