Aging Deer Jawbones

When aging a deer, only examine the lower jaw bone. Be sure to keep in mind:

- a **cusp** is a point or projection on the chewing surface of a tooth
- the 1st three teeth are premolars.
- the last three teeth are molars.
- **Dentine**= brown "stripe" on top of teeth

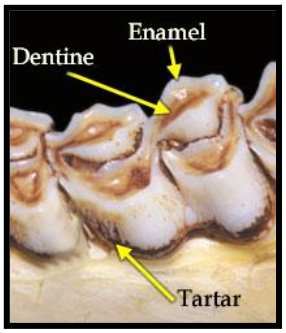
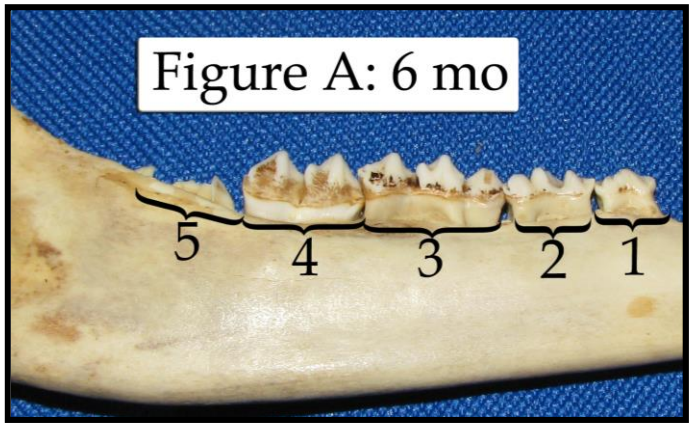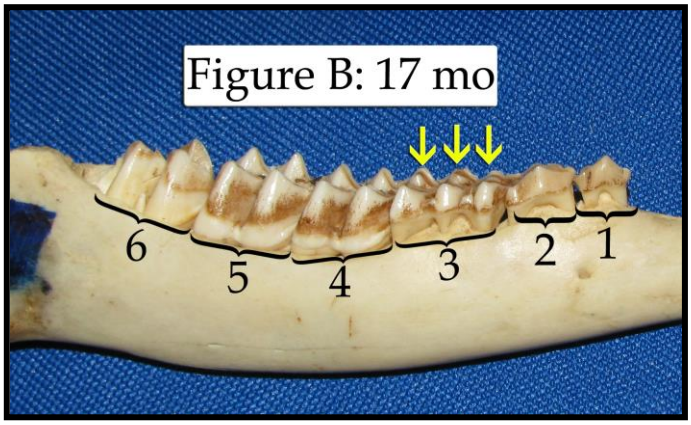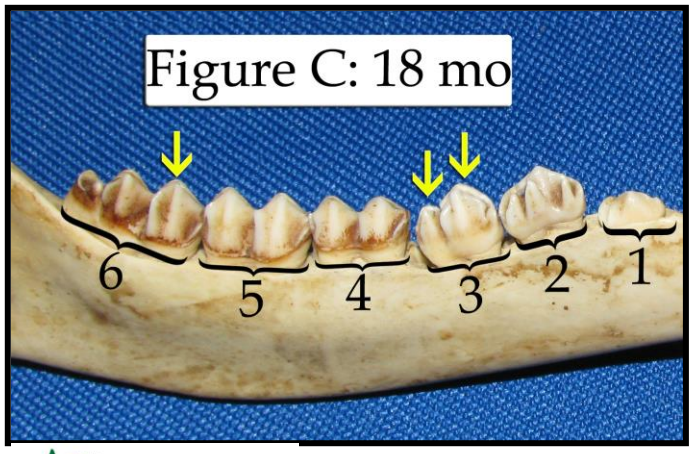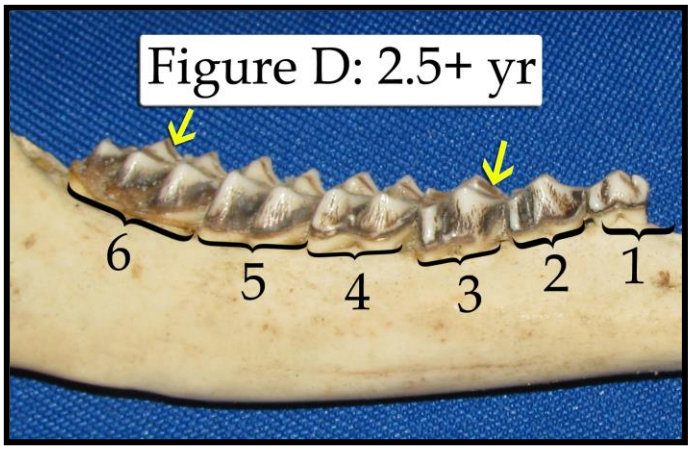
1. Four to five teeth present (premolars and molars); *Figure A*
    a. **Fawn** (6 months or less)
2. Six teeth present
    a. 3rd tooth tricusp; *Figure B*
        i. 1.5yr old (17mo)
    b. 3rd tooth bicusp
        i. 3rd tooth (bicusp premolar) has no wear or dentine evident and 6th tooth (molar) has no wear or dentine evident and may not be fully erupted; *Figure C*
            1. 1.5yr old (18 mo)
        ii. 3rd tooth (bicusp premolar) exhibits signs of wear and dentine "stripe" is evident and 6th tooth is worn with dentine "stripe" evident; *Figure D*
            1. 2.5+yr old